



Type 2 Diabetes (T2D) Case with Digestive and Cardiovascular Disorders Treated by EquMet and Twymeeeg

Naoki Kondo¹, Hiroshi Bando^{1,2,3id*}, Masaki Okada¹, Noboru Iwatsuki¹, Tomoya Ogawa¹, Kazuki Sakamoto¹

¹Sakamoto Hospital, Higashi Kagawa city, Kagawa, Japan

²Medical Research/Tokushima University, Tokushima, Japan

³Japan Low Carbohydrate Diet Promotion Association (JLCDPA), Kyoto, Japan

Corresponding Author: **Hiroshi BANDO, MD, PhD, FACP** [ORCID ID](#)

Address: Tokushima University /Medical Research, Nakashowa 1-61, Tokushima 770-0943, Japan;

Email: pianomed@bronze.ocn.ne.jp

Received date: 20 August 2023; **Accepted date:** 02 September 2023; **Published date:** 09 September 2023

Citation: Kondo N, Bando H, Okada M, Iwatsuki N, Ogawa T, Sakamoto K. Type 2 Diabetes (T2D) Case with Digestive and Cardiovascular Disorders Treated by EquMet and Twymeeeg. *Asp Biomed Clin Case Rep.* 2023 Sept 9;6(3):233-40.

Copyright © 2023 Kondo N, Bando H, Okada M, Iwatsuki N, Ogawa T, Sakamoto K. This is an open-access article distributed under the Creative Commons Attribution License, which permits unrestricted use, distribution, and reproduction in any medium provided the original work is properly cited.

Abstract

This case involves a 76-year-old female patient with type 2 diabetes (T2D), diabetic gastroenteropathy, and slight arteriosclerosis. Her HbA1c levels have been unstable for years due to her typical carbohydrate intake. Her symptoms include constipation, nausea, and abdominal fullness. Despite being on magnesium oxide and picosulfate, she experiences difficulty achieving smooth bowel movements for an extended period.

In March 2023, her HbA1c levels increased to 8.5%. Subsequently, EquMet and Twymeeeg were initiated, resulting in remarkable clinical effects, with her HbA1c dropping to 5.9% by August 2023. A Holter ECG recorded ventricular premature contractions (VPC) occurring 10 times (0.010%) over a 24-hour period. Additionally, plethysmography indicated a cardio-ankle vascular index (CAVI) of 9.5/9.3, suggesting slight arteriosclerosis.

Keywords

Diabetic Gastroenteropathy, Magnesium Oxide/Picosulfate, Twymeeeg, Plethysmography, Cardio-Ankle Vascular Index

Abbreviations

CAVI: Cardio-Ankle Vascular Index

Introduction

Diabetes has emerged as one of the crucial diseases in contemporary society worldwide [1]. It gives rise to various complications including macroangiopathy and microangiopathy. Among these, diabetic neuropathy (DN) stands out as the most common complication [2]. DN presents in two forms: i) sensory/motor neuropathy, manifesting as a common symmetric

polyneuropathy in the hands and feet, and ii) autonomic neuropathy affecting the gastrointestinal (GI) tract, cardiovascular (CV) system, and urogenital organs.

Diabetic gastroenteropathy constitutes one of the most prevalent complications among those suffering from prolonged diabetes [3]. It is frequently observed

in cases of diabetes characterized by poor glucose control and various other complications [4]. Symptoms encompass nausea, abdominal pain, vomiting, diarrhea, constipation, fecal incontinence, and irregular episodes of constipation and diarrhea. With the escalating number of diabetic patients, the management of these complications not only involves alleviating the primary symptoms but also achieving better glycemic control.

Of the multitude of diabetic symptoms, constipation emerges as a significant complication of both diabetic gastroenteropathy and diabetic microangiopathy. As the diabetic population ages, greater research emphasis is required to address GI tract issues in diabetic therapy [5]. Individuals with constipation often develop irregular eating habits due to abdominal discomfort, which can exacerbate glucose control and amplify various GI tract symptoms.

Conversely, diabetes brings about complications related to macroangiopathy. Atherosclerotic cardiovascular diseases (ASCVDs) frequently manifest and progress in individuals with long-standing diabetes. ASCVD encompasses conditions such as cerebral vascular accidents (CVAs), ischemic heart disease (IHD), and peripheral artery disease (PAD). Over years, post-prandial hyperglycemia (PPH) contributes to the development and exacerbation of macroangiopathy. In the pursuit of managing hyperglycemia, low carbohydrate diet (LCD) has demonstrated effectiveness [6]. The concept of LCD was pioneered by Atkins and Bernstein in Europe and North America, gaining worldwide prevalence [7,8]. In Japan, the Japan LCD Promotion Association (JLCDPA) was established by certain authors and their associates, fostering the medical and social advancement of LCD [9].

In terms of diabetes pharmacotherapy, novel oral hypoglycemic agents (OHAs) have been recently introduced, showcasing their clinical efficacy [10]. These include sodium-glucose cotransporter 2 inhibitors (SGLT2i), dipeptidyl peptidase-4 inhibitors (DPP-4i), and glucagon-like-peptide 1 receptor agonists (GLP1-RA). Additionally, imeglimin (Twymeeg) has garnered attention for its unique mechanism involving the mitochondrial pathway [11]. Its action involves

heightened insulin secretion and diminished insulin resistance [12]. Authors and their collaborators have undertaken extensive clinical research in the field of diabetes over a prolonged period [13]. Our team has encountered an intriguing diabetic case featuring several distinctive aspects. This report will outline the general status and offer some perspectives on the matter.

Case Presentation

Medical History:

The patient in this case is a 76-year-old female with type 2 diabetes (T2D), diabetic gastrointestinal issues, and cardiovascular complications spanning several years. She was diagnosed with T2D approximately 8 years ago and had been prescribed oral hypoglycemic agents (OHAs) at another medical clinic. Starting from 2019, she began receiving general treatments at our hospital (refer to **Fig-1**). Her HbA_{1c} levels exhibited erratic fluctuations ranging from 7% to 8%, and she consistently experienced gastrointestinal problems including constipation, abdominal fullness, nausea, and loss of appetite. Despite taking significant amounts of magnesium oxide and picosulfate, she faced challenges in achieving regular bowel movements. By March 2023, her HbA_{1c} had risen to 8.5%, leading to a change in her OHAs regimen from sitagliptin/metformin to EquMet (Equa and Metformin) (see **Fig-1**).

Physical Examination and Tests:

The physical examination revealed the following: vital signs were BP 128/80 mmHg, pulse 68/min, and SpO₂ 98%. The patient's consciousness and speech were within normal ranges. No significant abnormalities were noted during the examination of the lungs, heart, abdomen, or neurological system. The patient's measurements included a height of 155 cm, body weight of 57.3 kg, and a BMI of 23.9 kg/m².

As of January 2023, the biochemical test results were as follows: TP 7.2 g/dL, Alb 4.2 g/dL, AST 29 U/L, ALT 37 U/L, r-GT 32 U/L, ChE 72 U/L (30-200), uric acid 4.3 mg/dL, BUN 21 mg/dL, Cre 0.58 mg/dL, eGFR 74.8 mL/ml/1.73m², Na 143 mEq/L, Cl 102 mEq/L, K 3.9 mEq/L, amylase 70 U/L (37-125), LDL 112 mg/dL, HDL 71 mg/dL, TG 68 mg/dL, T-Cho 197 mg/dL, RBC 5.12 x

Case Report

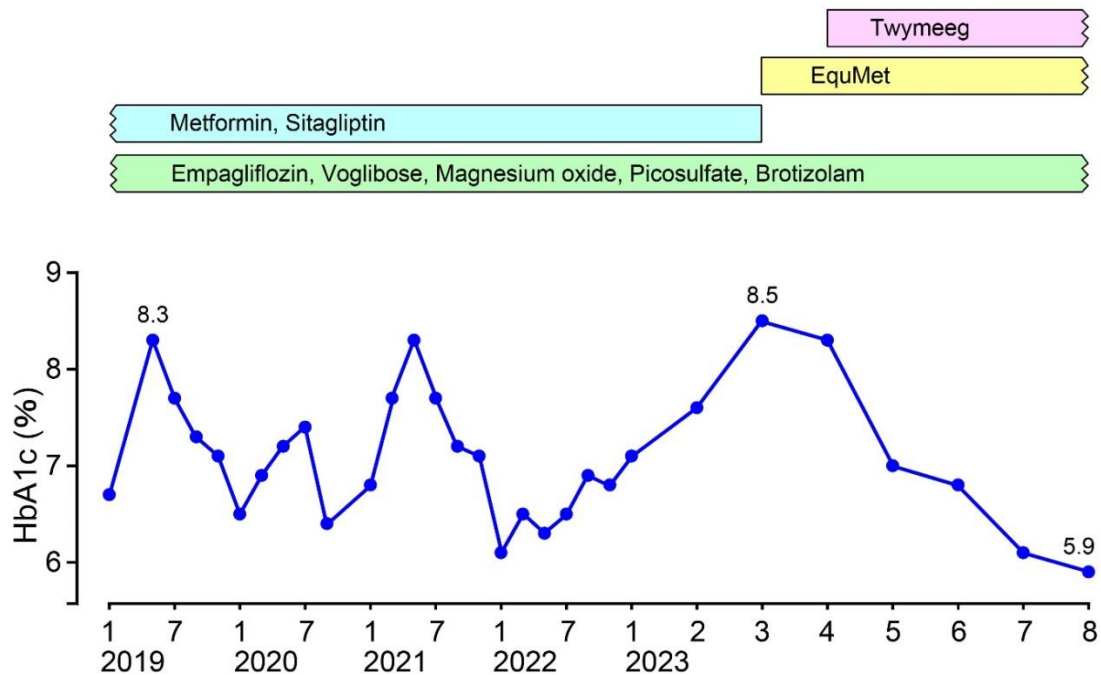


Fig-1: Clinical Progress of HbA1c and Treatment

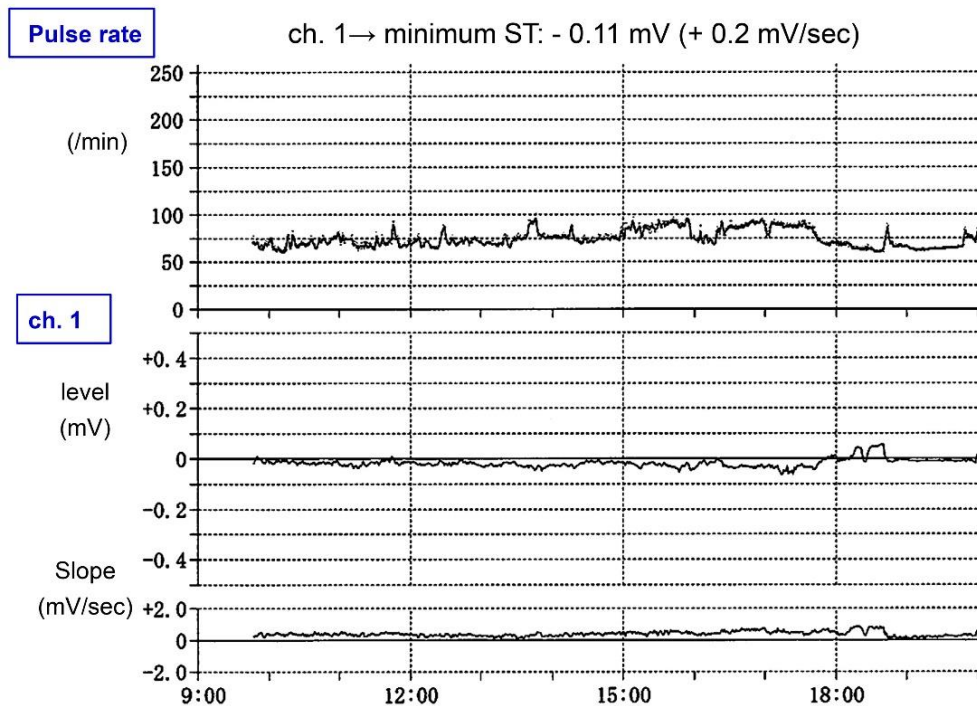


Fig-2: Finding of ST Trend in Holter ECG

10^6 / μ L, Hb 15.0 g/dL, Hct 46.1%, MCV 89.9 fL (80-98), MCH 29.3 pg (27-33), MCHC 32.6 g/dL (31-36), WBC 5600/ μ L, Plt 21.6×10^4 / μ L, CRP 0.09 mg/dL.

A chest X-ray showed unremarkable findings. The electrocardiogram (ECG) displayed a pulse rate of 72/min, a normal axis, and a sinus rhythm with occasional single ventricular premature contractions

(VPCs). On a Holter ECG exam, VPCs were observed 10 times over 24 hours, which accounted for 0.010% of the total 100,902 beats during that period. The ST trend analysis showed an average ST level of -0.01 mV, with a minimum ST value of -0.11 mV/sec and a maximum ST value of +1.0 mV/sec (Fig-2). These results indicated no significant findings related to ischemic heart disease (IHD) or arrhythmia issues.

Case Report

In January 2023, plethysmography was conducted, yielding the following results: ABI 1.16/1.12, CAVI 9.5/9.3, along with detailed data including PEP 83, ET 326, R-AI 0.98, and PEP/ET 0.26 (refer to Fig-3). These findings indicated unremarkable results in the

plethysmography assessment.

Clinical Progress

In March 2023, the patient's treatment was initiated with EquMet (Vildagliptin/Metformin), followed by the

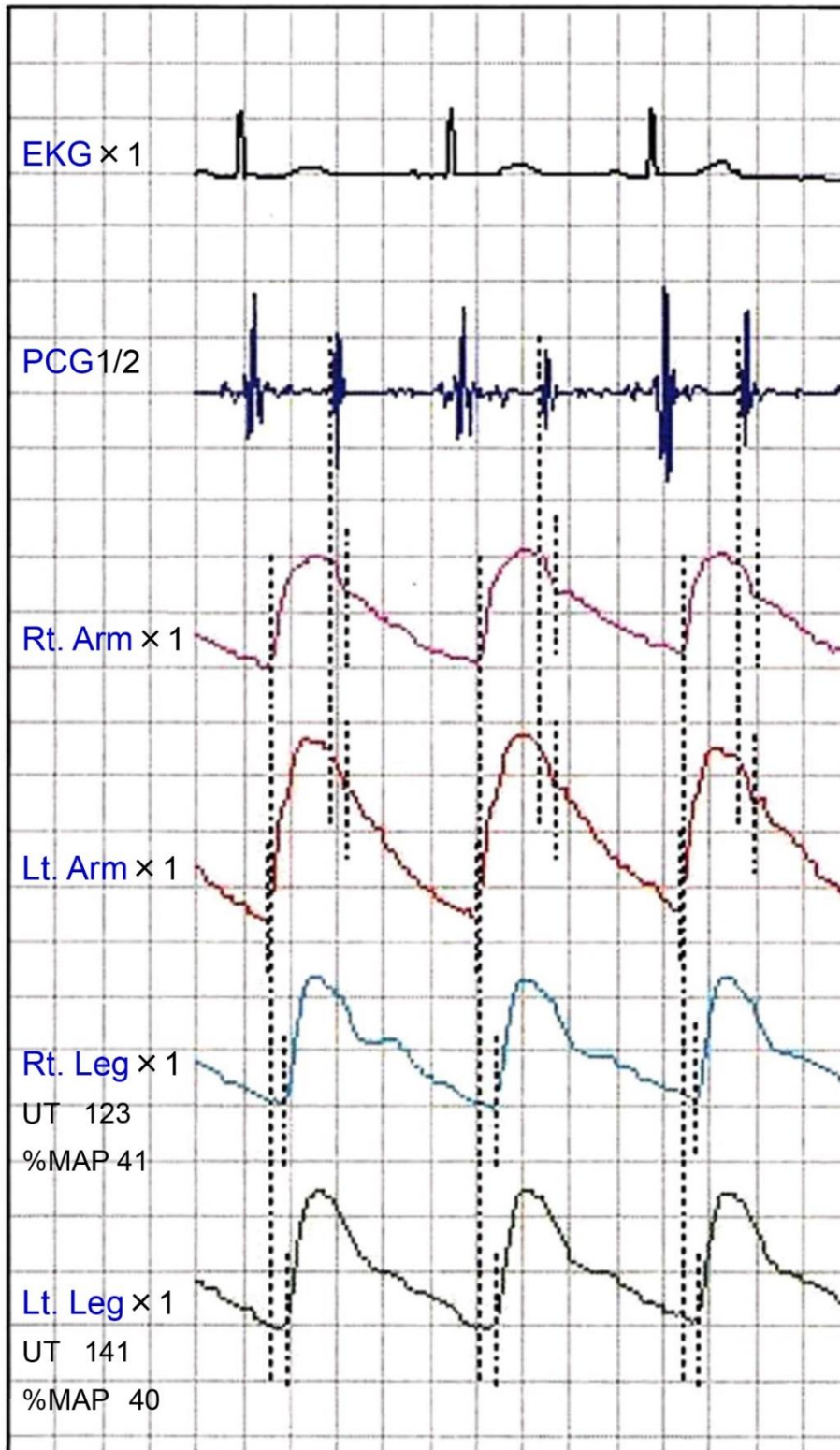


Fig-3: The Findings of Plethysmography

addition of Twymeeg (imeglimin). Through this combined therapeutic approach, a significant reduction in HbA_{1c} levels was achieved, reaching 5.9% by August 2023. Throughout this treatment period, no notable adverse effects on the gastrointestinal axis were observed (refer to **Fig-1**).

Ethical Considerations

The patient's participation in this study adhered to the ethical guidelines set forth in the Helsinki Declaration. Additionally, several principles outlined in the fundamental regulations were taken into account. These principles encompass ethical considerations related to both clinical practice and research methodologies. Given the presence of clinical implications for human subjects, the official guidelines established by the Japanese Ministries (specifically the Ministry of Health, Labor and Welfare, Ministry of Education, and Ministry of Culture, Sports, Science, and Technology) were followed.

The authors and collaborating researchers established an ethical committee based at Sakamoto Hospital in Higashi-Kagawa City, Kagawa Prefecture, Japan. This committee included various medical professionals, such as the hospital president, attending physician, pharmacist, head nurse, and legal experts. These team members engaged in thorough discussions to formulate an appropriate protocol and collectively agreed upon its details. Furthermore, informed consent was obtained from the patient through a documented process that aligned with the current case's requirements.

Discussion

The current case has highlighted certain characteristic points in the context of diabetic complications. These points include:

- i) prolonged unsatisfactory glucose control,
- ii) diabetic gastroenteropathy associated with various GI tract symptoms, such as nausea, constipation, abdominal pain, fecal incontinence, and others,
- iii) the presence of ASCVD as diabetic macroangiopathy, and
- iv) the effectiveness of novel oral hypoglycemic agents (OHAs) like EquMet and Twymeeg.

Several perspectives are outlined in this discussion.

First, this case has a preference for carbohydrate-rich meals such as bread, rice, and cakes. This is the main reason for the unsatisfactory control of blood glucose. When carbohydrates are ingested, blood glucose levels tend to rise for various individuals [14]. For the intake of 1g of carbohydrate, the increase in blood glucose levels would be around 1mg/dL for normal subjects, 3mg/dL for T2D, and 5 mg/dL for type 1 diabetes (T1D). Our diabetic team has proposed convenient LCD methods [9], namely super-LCD, standard-LCD, and petite-LCD, which contain carbohydrate amounts of 12%, 26%, and 40% of the calorie ratio, respectively [15].

Second, this case has been dealing with diabetic gastroenteropathy for an extended period, particularly focusing on constipation. She has been using magnesium citrate and picosulfate for years [16]; however, they did not exhibit sufficient clinical efficacy [17]. Several factors contribute to the development of diabetic gastroenteropathy. These factors include hyperglycemia, a large mean amplitude of glycemic excursions (MAGE), vagal dysfunction, oxidative stress, decreased expression of neural nitric oxide synthase (NOS), and others. Among diabetic patients, about 70% experience more GI discomfort compared to individuals without diabetes, and 25% of diabetic cases have previously reported experiencing GI tract symptoms. Diabetic enteropathy can affect the entire GI tract, with constipation observed in 60% of cases and diarrhea in 20% [18].

Third, the current case showed potential influences of arteriosclerosis in Holter ECG and plethysmography examinations. The values of Cardio-Ankle Vascular Index (CAVI) are utilized for evaluating arteriosclerosis and are influenced by certain exacerbating factors [19]. These factors include blood pressure, blood glucose levels, and LDL cholesterol levels [20]. Consequently, arterial stiffness is assessed using pulse wave velocity (PWV) [21]. The Arterial Stiffness Index (ASI) has recently gained attention for quantifying the degree of arteriosclerosis. ASI has been shown to predict the worsening of systolic hypertension with an odds ratio of 1.30 [20]. Additionally, the LDL cholesterol value in the lipid profile might contribute to arterial stiffness

and impact carotid intima-media thickness results [22].

Fourth, this case was treated with both EquMet and Twymeeg, both of which appeared to be effective. Regarding the clinical effects of EquMet, the VERIFY study reported international project findings [23]. Medical efficacy was evaluated in comparison with metformin monotherapy and combined vildagliptin/metformin treatment. Among cases over 40 years old, add-on treatment demonstrated a 46% decrease in the risk of cardiovascular events [24]. Furthermore, Twymeeg exhibited a significant reduction in HbA1c levels with notable clinical efficacy. Findings from the international investigation "Trials of Imeglimin for Efficacy and Safety (TIMES) 1, 2, and 3" included assessments of both monotherapy and combination treatments [25]. The combined effects revealed a reduction of -0.67% for biguanides and -0.92% for DPP4 inhibitors [26]. Imeglimin operates through an impressive novel mechanism involving the mitochondrial route [27].

There may be certain limitations in this report. While the clinical efficacy in decreasing HbA1c levels primarily resulted from Twymeeg, other factors also played a combined role. This case involves multiple elements, warranting close follow-up and attention.

In summary, this report discusses a 76-year-old female with Type 2 Diabetes (T2D), digestive issues, and signs of arteriosclerosis. Notably, she experienced a significant reduction in HbA1c levels with Twymeeg. It is hoped that this report will provide valuable data for future research in the field of diabetes.

Conflict of Interest

The authors have read and approved the final version of the manuscript. The authors have no conflicts of interest to declare.

Funding

There was no funding received for this paper.

References

[1] ElSayed NA, Aleppo G, Aroda VR, Bannuru RR, Brown FM, Bruemmer D, Collins BS, Hilliard ME,

Isaacs D, Johnson EL, Kahan S, Khunti K, Leon J, Lyons SK, Perry ML, Prahalad P, Pratley RE, Seley JJ, Stanton RC, Gabbay RA, on behalf of the American Diabetes Association. 1. Improving Care and Promoting Health in Populations: Standards of Care in Diabetes-2023. *Diabetes Care.* 2023 Jan 1;46(Suppl 1):S10-18. [PMID: 36507639]

[2] Quiroz-Aldave J, Durand-Vásquez M, Gamarra-Osorio E, Suarez-Rojas J, Jantine Roseboom P, Alcalá-Mendoza R, Coronado-Arroyo J, Zavaleta-Gutiérrez F, Concepción-Urteaga L, Concepción-Zavaleta M. Diabetic neuropathy: Past, present, and future. *Caspian J Intern Med.* 2023 Spring;14(2):153-69. [PMID: 37223297]

[3] ElSayed NA, Aleppo G, Aroda VR, Bannuru RR, Brown FM, Bruemmer D, Collins BS, Cusi K, Hilliard ME, Isaacs D, Johnson EL, Kahan S, Khunti K, Leon J, Lyons SK, Perry ML, Prahalad P, Pratley RE, Seley JJ, Stanton RC, Gabbay RA, on behalf of the American Diabetes Association. 4. Comprehensive Medical Evaluation and Assessment of Comorbidities: Standards of Care in Diabetes-2023. *Diabetes Care.* 2023 Jan 1;46(Suppl 1):S49-67. Erratum in: *Diabetes Care.* 2023 Jun 25;: Erratum in: *Diabetes Care.* 2023 Sep 1;46(9):1718-20. [PMID: 36507651]

[4] Kurniawan AH, Suwandi BH, Kholili U. Diabetic Gastroenteropathy: A Complication of Diabetes Mellitus. *Acta Med Indones.* 2019 Jul;51(3):263-71. [PMID: 31699951]

[5] Wei L, Ji L, Miao Y, Han X, Li Y, Wang Z, Fu J, Guo L, Su Y, Zhang Y. Constipation in DM are associated with both poor glycemic control and diabetic complications: Current status and future directions. *Biomed Pharmacother.* 2023 Sep;165:115202. [PMID: 37506579]

[6] Feinman RD. The biochemistry of low-carbohydrate and ketogenic diets. *Curr Opin Endocrinol Diabetes Obes.* 2020 Oct;27(5):261-68. [PMID: 32796164]

[7] Bernstein RK. Dr. Bernstein's Diabetes Solution - The Complete Guide to Achieving Normal Blood Sugars. New York: Little, Brown and company; 1997. Available from:

<https://www.hachettebookgroup.com/titles/richard-k-bernstein-md/dr-bernsteins-diabetes-solution/9780316191739/?lens=little-brown>

[8] Robert RC. Dr. Atkins' New Carbohydrate Gram Counter: More Than 1200 Brand-Name and Generic

Foods Listed with Carbohydrate, Protein, and Fat Contents. New York: M. Evans and Company; 1996.

[9] Muneta T, Hayashi M, Nagai Y, Matsumoto M, Bando H, et al. Ketone Bodies in the Fetus and Newborn During Gestational Diabetes and Normal Delivery. *Int J Diabetes.* 2023;5(1):157-63.

[10] Singh AK, Singh A, Singh R, Misra A. Efficacy and safety of imeglimin in type 2 diabetes: A systematic review and meta-analysis of randomized placebo-controlled trials. *Diabetes Metab Syndr.* 2023 Feb;17(2):102710. [PMID: 36702046]

[11] Yanai H, Adachi H, Hakoshima M, Katsuyama H. Glucose-Lowering Effects of Imeglimin and Its Possible Beneficial Effects on Diabetic Complications. *Biology (Basel).* 2023 May 16;12(5):726. [PMID: 37237539]

[12] Bando H. Dual action mechanism of insulin resistance and insulin secretion by imeglimin for diabetic treatment. *Diabetes Res Open J.* 2022;8(1):e1-e3.

[13] Okada M, Bando H, Iwatsuki N, Sakamoto K, Ogawa T. Relieved Depressive State and Glycemic Control in Type 2 Diabetes (T2D) Patient Treated by Imeglimin (Twymeeg). *Asp Biomed Clin Case Rep.* 2023 Jun 12;6(2):116-23.

[14] McGuinness OP. Chapter 19: Gluconeogenesis & the Control of Blood Glucose. Kennelly P.J., & Botham K.M., & McGuinness O.P., & Rodwell V.W., & Weil P(Eds.). United States: Harper's Illustrated Biochemistry, 32e. McGraw Hill; 2023.

[15] Bando H. Useful Tips for Actual Low Carbohydrate Diet (LCD) with Super-, Standard- and Petit-LCD Methods. *EC Nutrition.* 2020;15(5):1-4.

[16] de Miranda Neto AA, de Moura DTH, Hathorn KE, Tustumi F, de Moura EGH, Ribeiro IB. Efficacy and Patient Tolerability of Split-Dose Sodium Picosulfate/Magnesium Citrate (SPMC) Oral Solution Compared to the Polyethylene Glycol (PEG) Solution for Bowel Preparation in Outpatient Colonoscopy: An Evidence-Based Review. *Clin Exp Gastroenterol.* 2020 Oct 7;13:449-57. [PMID: 33116741]

[17] Okamoto N, Tanaka S, Abe H, Miyazaki H, Nakai T, Tsuda K, Sakaguchi H, Yoshizaki T, Ikezawa N, Inoue J, Ooi M, Kodama Y. Predicting Inadequate Bowel Preparation When Using Sodium Picosulfate plus Magnesium Citrate for Colonoscopy: Development and Validation of a Prediction Score. *Digestion.*

2022;103(6):462-69. [PMID: 36380621]

[18] Concepción Zavaleta MJ, Gonzáles Yovera JG, Moreno Marreros DM, Rafael Robles LDP, Palomino Taype KR, Soto Gálvez KN, Arriola Torres LF, Coronado Arroyo JC, Concepción Urteaga LA. Diabetic gastroenteropathy: An underdiagnosed complication. *World J Diabetes.* 2021 Jun 15;12(6):794-809. [PMID: 34168729]

[19] Vallée A, Safar ME, Blacher J. Application of a decision tree to establish factors associated with a nomogram of aortic stiffness. *J Clin Hypertens (Greenwich).* 2019 Oct;21(10):1484-92. [PMID: 31479194]

[20] Webb AJS. Progression of Arterial Stiffness is Associated with Midlife Diastolic Blood Pressure and Transition to Late-Life Hypertensive Phenotypes. *J Am Heart Assoc.* 2020 Jan 7;9(1):e014547. [PMID: 31902329]

[21] Vallée A. Arterial stiffness nomogram identification by cluster analysis: A new approach of vascular phenotype modeling. *J Clin Hypertens (Greenwich).* 2022 Nov;24(11):1415-26. [PMID: 36196587]

[22] Jia X, Qi Y, Zheng R, Lin L, Hu C, Zhu Y, Cao Q, Wu X, Qi H, Wei R, Zhang Y, Xu M, Xu Y, Wang T, Zhao Z, Chen Y, Li M, Wang W, Bi Y, Lu J. Discordance of Apolipoprotein B, Non-HDL-Cholesterol, and LDL-Cholesterol Predicts Risk of Increased Arterial Stiffness and Elevated Carotid Intima-Media Thickness in Middle-Aged and Elderly Chinese Adults. *Front Cardiovasc Med.* 2022 May 18;9:906396. [PMID: 35665267]

[23] Matthews DR, Paldánus PM, Proot P, Chiang Y, Stumvoll M, Del Prato S; VERIFY study group. Glycaemic durability of an early combination therapy with vildagliptin and metformin versus sequential metformin monotherapy in newly diagnosed type 2 diabetes (VERIFY): a 5-year, multicentre, randomised, double-blind trial. *Lancet.* 2019 Oct 26;394(10208):1519-29. [PMID: 31542292]

[24] Chan JCN, Paldánus PM, Mathieu C, Stumvoll M, Matthews DR, Del Prato S. Early combination therapy delayed treatment escalation in newly diagnosed young-onset type 2 diabetes: A subanalysis of the VERIFY study. *Diabetes Obes Metab.* 2021 Jan;23(1):245-51. [PMID: 32894637]

[25] Dubourg J, Fouqueray P, Thang C, Grouin JM,

Case Report

Ueki K. Efficacy and Safety of Imeglimin Monotherapy Versus Placebo in Japanese Patients With Type 2 Diabetes (TIMES 1): A Double-Blind, Randomized, Placebo-Controlled, Parallel-Group, Multicenter Phase 3 Trial. *Diabetes Care.* 2021 Apr;44(4):952-59. [PMID: 33574125]

[26] Dubourg J, Fouqueray P, Quinslot D, Grouin JM, Kaku K. Long-term safety and efficacy of imeglimin as monotherapy or in combination with existing

antidiabetic agents in Japanese patients with type 2 diabetes (TIMES 2): A 52-week, open-label, multicentre phase 3 trial. *Diabetes Obes Metab.* 2022 Apr;24(4):609-19. [PMID: 34866306]

[27] Hozumi K, Sugawara K, Ishihara T, Ishihara N, Ogawa W. Effects of imeglimin on mitochondrial function, AMPK activity, and gene expression in hepatocytes. *Sci Rep.* 2023 Jan 13;13(1):746. [PMID: 36639407]

